



CASE SERIES

Uncommon skin and soft tissue infections encountered in adults and children caused by different aerobic, anaerobic bacteria and protistan organism: A series of cases from Kolkata, India

Ananda Sanchayeeta Mandal, Dipankar Paul, Hossain Najma Banu,
Asis Kumar Ghosh, Hirak Jyoti Raj, Hasina Banu

Abstract

Skin and soft tissue infections (SSTIs) result from microbial invasion and may be mono or polymicrobial in etiology. The present retrospective record based study described five uncommon SSTIs from a medical college hospital of West Bengal. Clinical samples were collected and processed following standard microbiological procedures and guidelines. Identification and antimicrobial susceptibility testing of etiological agents, wherever applicable, were done by conventional and automated (Vitek-2 Compact) system. We found a case of spontaneous gas gangrene caused by *Clostridium septicum*, Group-A α -hemolytic *Streptococcus* mediated necrotizing fasciitis; lesions of *Burkholderia pseudomallei* and *Burkholderia cepacia complex* and that of disseminated rhinosporidiosis caused by *Rhinosporidium seeberi*. We infer that strong clinical suspicion may surface uncommon etiology from unusual presentations of SSTIs making their diagnosis, treatment and relief rapid and uneventful.

Keywords

SSTIs, Gas Gangrene, Burkholderia, Rhinosporidiosis, Uncommon

Introduction

Skin and soft tissue infections (SSTIs) resulting from microbial invasion of the skin and its appendages are the one of the most common infections acclaimed globally and in India having an incidence rate of 18.21 per 1000 person-year in 2021^[1] SSTIs can be classified as uncomplicated vs complicated, or as suppurative or non-suppurative. Most community-acquired infections are caused by methicillin-resistant *Staphylococcus aureus* (MRSA) and beta-hemolytic *Streptococci*. Simple infections are usually monomicrobial; on the contrary, complicated infections are mono- or polymicrobial usually

presenting with systemic inflammatory response syndrome. The diagnosis of SSTIs is predominantly clinical, where, laboratory has role of confirmation only by varieties of systemic investigations including microbiological investigations. Patients with complicated infections, including suspected necrotizing fasciitis and gas gangrene, require empiric polymicrobial antibiotic coverage, inpatient treatment, and surgical debridement^[2]. Blind and unwise use of antibiotics in empirical therapy invites emergence of drug resistant pathogens.

Material and methods

Copyright: © 2024 JK Science. This is an open access journal, and articles are distributed under the terms of the Creative Commons Attribution-NonCommercial-ShareAlike 4.0 International License, which allows others to remix, transform, and build upon the work, and to copy and redistribute the material in any medium or format non-commercially, provided the original author(s) and source are credited and the new creations are distributed under the same license.

Cite this article as: Manda AS, Paul D, Banu HN, Ghosh AK, Raj HJ, Banu H. Uncommon skin and soft tissue infections encountered in adults and children caused by different aerobic, anaerobic bacteria and protistan organism: a series of cases from Kolkata, India. JK Science 2024;26(2):130-133.

Department of Microbiology, IPGME&R-SSKM Hospital, Kolkata, West Bengal, Pin-700020, India.

Correspondence to: Dr. Hirak Jyoti Raj, Associate Professor, Dept of Microbiology, IPGME&R-SSKM Hospital, Kolkata, West Bengal, Pin-700020.

Manuscript Received: 22.06.2023; Revision Accepted: 26.8.2023

Published Online First: 10 April, 2024.

Open Access at: <https://journal.jkscience.org>



The present case series is a retrospective, cross-sectional, observational study presenting some unusual cases of SSTIs. Following collection, the specimens were processed both aerobically and anaerobically as per standard textbook guidelines¹³. Identification and antibiotic susceptibility testing (AST) were done by conventional technique and automated system (VITEK-2, BioMerieux), where required.

Case 1: A male gardener, 42 years, was admitted to ICU with history of bilateral swelling from groin to feet and intense pain. On examination, subcutaneous crepitations were detected in left hypochondrium and blue-black bullous lesions containing watery fluid followed by sloughing off of the skin overlying the lower extremities, which rapidly progressed to extensive sloughing of skin and soft tissue (Fig. 1a). There was no history of trauma. The patient complained of postprandial anorexia with development of excruciating pain in both lower limbs followed by blister formation of the overlying skin of lower extremities. There was no history of immuno-suppression or chronic illness or any regular intake of medication. On admission, investigations revealed raised TLC (17000/cmm) with neutropenia, anaemia and dyselectrolytemia. Radiological investigations revealed gas under diaphragm and distended bowel loops. Computed Tomogram (CT) scan of abdomen showed pneumatosis intestinalis. Samples collected were blister fluid, exudates and sloughs from the depth of the wound, for both aerobic and anaerobic study. Direct gram stain showed absence of acute inflammatory cells with stout gram positive bacilli with sub-terminal spores and few gram positive cocci (Fig. 1b). Culture in Robertson's Cooked Meat (RCM) broth showed pleomorphic Gram-positive bacilli with oval, sub-terminal spores (Fig. 1c). The paucity of inflammatory cells in sample and location of endospores were suggestive of *Clostridium septicum*¹⁴. This gangrenous process was thought to be spontaneous. *Clostridium septicum* is regarded as the most common cause of spontaneous gas gangrene. Patient was put on mechanical ventilation with ceftazidime, amikacin and metronidazol. Despite all measures, he remained unresponsive to therapy and succumbed to death.

Case 2: A 55year old diabetic male patient presented to emergency department with H/O ulcerative lesion over dorsomedial aspect of the right foot with purulent foul-smelling discharge (Fig. 2). He had an ankle sprain about a fortnight ago for which he applied hot water fomentation consequent to scalding and sloughing off of the superficial skin. The course of the wound was rapidly progressive with exposure of fascial plane. It was suspected as gas gangrene and we collected wound swabs from the depth

of the wound and deep wound exudates. Direct gram staining of the samples showed presence of poly-microbial flora comprising of Gram-negative bacilli (GNB) and Gram positive cocci (GPC) in short chains. No boxcar shaped bacillus suggestive of *Clostridium perfringens* was found. ZN stain didn't reveal any acid-fast bacilli. Aerobic culture showed mixed bacterial growth. Anaerobic culture was non-contributory. Sample was inoculated into Todd-Hewitt medium followed by sub culture in 5% Sheep Blood Agar (SBA) and incubated with 5% CO₂ for 48 hrs; using candle jar technique. The SBA plates showed growth of hemolytic colonies¹⁵. Gram staining revealed GPC in short and medium chains. Biochemically they were catalase -, oxidase -, CAMP - and bacitracin sensitive. The diagnosis of *Streptococcus pyogenes* was established. Rapid progression, involvement of deeper tissues and destructive lesion resembled characteristics of necrotizing fasciitis. The patient was put on penicillin and clindamycin followed by extensive surgical debridement. He was finally discharged with the advice of strict glycemic control.

Case 3: A 48 year old diabetic ration-dealer was suffering from intermittent fever, myalgia, localized nodules on the back, buttock, thigh, which progressed to form multiple abscesses for quite a long duration. He was treated with antibiotics, skin lotions and oral steroids. For investigation, pus sample was collected from the lesions of the thigh and sent to Microbiology. According to the suspicion of the Infectious disease clinicians, it was processed under BSL-2 cabinet. Culture was done aerobically in 5% SBA, MacConkey's agar and brucella blood agar. Anaerobic culture was sterile. Aerobic culture showed dry, wrinkled, small, tan or cream-colored shiny colonies in 5% SBA and non lactose fermenter colonies (NLF) in MacConkey's agar (Fig 3). The organisms were non-fermenter, oxidase positive, nitrate reduction test positive motile GNB and finally diagnosed as *Burkholderia pseudomallei* by VITEK-2 compact system. Blood culture from the patient was non-contributory. Based on AST reports, he was treated with intravenous ceftazidime for four weeks followed by oral Amoxicillin-clavulanate for 6 months¹⁶.

Case 4: A 15 year old child was admitted with H/O paraplegia due to spinal cord injury (SCI). He was diagnosed to have laboratory confirmed nocardia osteomyelitis and was on treatment. However, during his hospital stay, he developed multiple non-healing ulcers on the front and back of torso along with fever, vomiting, diarrhea and anorexia (Fig. 4). His hematological and biochemical parameters were within normal range excepting a raised CRP and high liver enzymes. We

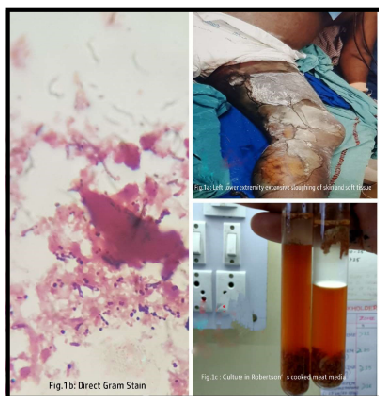

Fig.1a showing left leg extremity extensive sloughing of skin and soft tissue Fig.1b showing Direct Gram Stain Fig.1c showing Culture in Robertson's cooked meat media

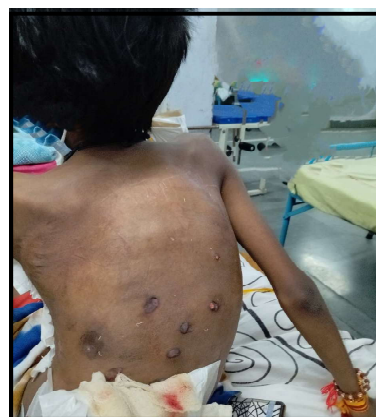

Fig.4 showing multiple non healing ulcers.

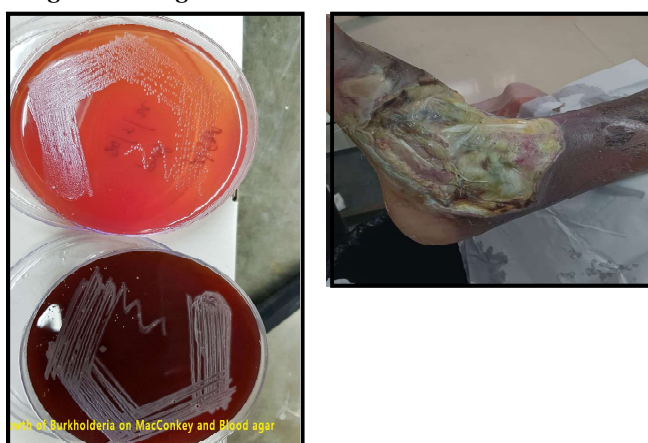

Fig.2 showing ulcerative lesion on the right foot Fig.3 showing growth of Burkholderia on Mac Conkey and Blood agar.

collected the pus samples from the multiple abscesses aseptically. Direct Gram stain from pus revealed plenty of GNB. ZN stain and KOH mount were non-contributory. Aerobic culture on MacConkey's agar and 5% SBA showed growth of oxidase positive, catalase producing NLF GNB colonies. Anaerobic culture and fungal culture were sterile. The final diagnosis was made by VITEK-2 compact system, as *Burkholderia cepacia*. He was treated accordingly with ceftazidime, carbapenems, followed by cotrimoxazole and responded well to therapy and was discharged with the advice to follow up.

Case 5: A 35yr old milkman from a village of West Bengal was admitted under Dept of Dermatology, with H/O multiple fungating growths over face, left forearm, both legs for over nine months (Fig 5a). He had a previous H/O polypoidal nasal growth, in left nostril, operated around five years back and similar looking leg lesion treated by excision with split thickness skin graft about

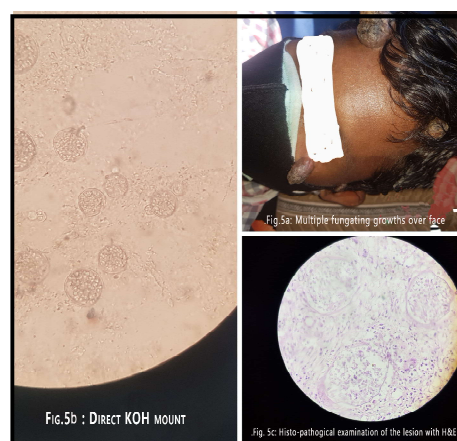


Fig.5a showing multiple fungating growths over face. Fig.5b showing Direct KOH mount Fig. 5c showing Histo-pathological examination of the lesion with H&E.

three years ago. The patient gave history of taking bath in village ponds along with his own cattles on regular basis. Though there was suspicion of rhinosporidiosis, there was no nasal lesion. Routine investigations were within normal range. There was no H/O of diabetes, hypertension or tuberculosis. Excision biopsy sent for histopathological and microbiological investigations. ZN stain showed no acid fast structure. But both Gram and ZN stain revealed some sac like structures, the details of which could not be discerned. KOH wet mount from the teased specimen revealed sporangia filled up with endospores at various stages (Fig 5b). Microbiological culture remained unyielding. MRI of the bilateral thigh showed the impression of multiple T1 hypointense and T2/STIR hyperintense lesions in the subcutaneous tissue with extensive subcutaneous oedema and necrosis in the largest lesion. Histopathological examination with H&E (Fig. 5c) and Giemsa stained slide showed pathognomonic endosporulating sporangia of *Rhinosporidium seeberi*



in various stages of development. Inability to grow on artificial culture media further confirmed the diagnosis of Rhinosporidiosis. All cutaneous lesions were excised radically and the patient was started on Tab. Dapsone 100 mg to be continued and advised for routine follow-up.

Discussion

Gas gangrene is a life-threatening myonecrosis and well-recognized complication of trauma and penetrating wounds like war wounds, septic abortion or surgical intervention^[7]. It is a polymicrobial infection caused by various anaerobic organisms namely *Clostridium perfringens*, *Clostridium septicum*, *Cl. novyi*, *Cl. bifermentans*, *Cl. histolyticum* *Cl. fallax*. *C.septicum* produces a toxin lacking phospholipase activity, alpha-toxin, beta toxin and W toxin. All these may cause myonecrosis without any preceding trauma^[8]. The theory of mucosal ulceration as the portal was supported by Abella et al. where a patient with radiation colitis had had spontaneous *Cl. septicum* gas gangrene^[9]. GAS cause various soft tissue infections including necrotizing fasciitis^[10]. Spread of necrosis occurs along the fascial planes to involve the adjacent soft tissue and muscles^[11]. Necrotizing fasciitis is also caused by *Staphylococcus aureus*. Two necrotizing fasciitis cases caused by *Staphylococcus aureus* were reported in lymphatic filariasis (LF) patients from South India. The researchers found that the secondary bacterial infections were due to poor skin hygiene, comorbidities and contamination during LF wound dressing^[12]. Melioidosis is an infection caused by *Burkholderia pseudomallei*. Definite diagnosis of melioidosis, depends on isolation of *B.pseudomallei* from clinical specimens. Infection is acquired by contact/ingestion of dust, contaminated water soil through skin abrasions. It is considered as potential agent for bioterrorism^[13]. Melioidosis has been dubbed the "Vietnamese time bomb" because the disease may still be incubating in American veterans of the Vietnam conflict^[14].

B. cepacia complex (BCC), found in soil and water, has emerged as a cause of opportunistic human infections, particularly in patients of chronic granulomatous disease and cystic fibrosis. They rarely cause community-acquired infections outside the respiratory tract. They can survive in the presence of disinfectants, hence, are the potential source of nosocomial infections. Rola KW et al found BCC in central line associated bacteremia (17/44, 38.6%)^[15]. Rhinosporidiosis a chronic granulomatous disease characterized by polyposis of nasal cavity, conjunctiva and other mucosal and non-mucosal body sites. It is caused by *Rhinosporidium seeberi*, a debated endo-sporulating

aquatic organism, hyperendemic in Indian subcontinent. In recent past, giant lesions and disseminated type of the disease has been reported in some clinical settings.

Conclusion

SSTIs are very commonly encountered in daily practices. Clinical suspicion based on history, course and background may unveil uncommon etiology and ensure quick treatment.

References

1. Singh M, Immanuel G, Kannan A. Antimicrobial susceptibility profile of *Staphylococcus aureus* isolates obtained from skin and soft tissue infections: A real-world study based on a large diagnostic laboratory data. *JIMA*. March 2021; 119 (3):21-7.
2. Burnham JP, Kirby JP, Kollef MH. Diagnosis and management of skin and soft tissue infections in the intensive care unit: a review. *Intensive Care Med*. 2016;42(12):1899-1911.
3. Tille, Patricia M. Bailey & Scott's Diagnostic Microbiology. 14th ed. St. Louis, Missouri: Elsevier; 2017.72-110p.
4. Stevens D, Musher D, Watson D, Eddy H, Hamill R, Gyorkey F. et al. Spontaneously nontraumatic gangrene due to *Clostridium septicum*. *Rev Infect Dis*. 1990; 12: 286-96.
5. Procop, Gary W. Koneman's Color atlas and textbook of diagnostic microbiology. 7th ed. Philadelphia: Wolters Kluwer Health; 2017. 782 p.
6. Dance D. Treatment and prophylaxis of melioidosis. *Int J Antimicrob Agents*. 2014 Apr; 43(4):310-8.
7. Preseau T, Deviend J, Duttman R, Attou R, Franck D, Claeys R et al. *Clostridium Perfringens* in Gas Gangrene: Still a Smoked Gun! *J Transl Int Med*. 2020 May;8(1):54-6.
8. Procop, Gary W, Koneman's Color atlas and textbook of diagnostic microbiology. 7th ed. Philadelphia: Wolters Kluwer Health; 2017. 1006p
9. Abella BS, Kuchinic P, Hiraoka T, Howes DS. Atraumatic Clostridial myonecrosis: case report and literature review. *J Emerg Med*. 2003 May; 24(4):401-5.
10. Jamal N, Teach SJ. Necrotizing fasciitis. *Pediatr Emerg Care*. 2011 Dec;27(12):1195-9.
11. Procop, Gary W, Koneman's Color atlas and textbook of diagnostic microbiology. 7th ed. Philadelphia: Wolters Kluwer Health; 2017. 744-5p.
12. Maramraj KK, MI KL, Dikid T, Choudhary S, Reddy S, Jain SK, Singh SK. An outbreak of acute skin and soft tissue infections including necrotizing fasciitis in Kalwala village, India, 2018: Public health implications for the lymphatic filariasis elimination program. *Trans R Soc Trop Med Hyg*. 2020 Oct 5;114(10):742-750.
13. <http://wwwnc.cdc.gov/travel/yellowbook/2020/travel-related-infectious-diseases/melioidosis>.
14. Goshorn RK. Recrudescence pulmonary melioidosis: a case report involving the so called "Vietnamese time bomb". *Indiana Med* 1987; 80:247-9.
15. Kwayess R, Al Hariri HE, Hindy JR, Youssef N, Haddad SF, Kanj SS. *Burkholderia cepacia* Infections at Sites Other than the Respiratory Tract: A Large Case Series from a Tertiary Referral Hospital in Lebanon. *J Epidemiol Glob Health*. 2022 Sep;12(3):274-280.